

# Endolymphatic hydrops and fluctuating hearing loss in a patient with congenital cytomegalovirus infection

Lucia C.M. Grijpink<sup>a,\*</sup>, Ann C.T.M. Vossen<sup>a</sup>, Tjasse D. Bruintjes<sup>b</sup>, Berit M. Verbist<sup>c</sup>, Heiko Locher<sup>b,d</sup>, Liselotte J.C. Rotteveel<sup>b</sup>

<sup>a</sup> Department of Medical Microbiology, Leiden University Medical Center, Albinusdreef 2, 2333 ZA, Leiden, the Netherlands

<sup>b</sup> Department of Otorhinolaryngology and Head & Neck Surgery, Leiden University Medical Center, Albinusdreef 2, 2333 ZA, Leiden, the Netherlands

<sup>c</sup> Department of Radiology, Leiden University Medical Center, Albinusdreef 2, 2333 ZA, Leiden, the Netherlands

<sup>d</sup> The Novo Nordisk Foundation Center for Stem Cell Medicine (reNEW), Leiden University Medical Center, Albinusdreef 2, 2333 ZA, Leiden, the Netherlands

## ARTICLE INFO

### Keywords:

Cytomegalovirus  
Endolymphatic hydrops  
Hearing loss  
Magnetic Resonance Imaging  
Meniere disease  
Tinnitus

## ABSTRACT

Congenital cytomegalovirus (cCMV) infection can cause fluctuating hearing loss and vestibulopathy. The pathogenesis is unknown. This report describes a 13-year old boy with cCMV and severe hearing loss in the right ear since age 3, presenting with fluctuating hearing loss in the left ear and vestibular symptoms. 3D fluid attenuated inversion recovery (FLAIR) MRI showed endolymphatic hydrops in the acutely affected ear. This is the first description of a child with cCMV subjected to this imaging technique, raising the question whether endolymphatic hydrops could play a role in the development of late-onset symptoms and demonstrating the possibilities of this MRI sequence.

## 1. Introduction

Congenital cytomegalovirus infection (cCMV) occurs in 0.5–6% of pregnancies and is the most common non-genetic cause of hearing loss [1,2]. The most prevalent symptoms of cCMV are hearing loss and vestibulopathy, each of which occurs in 14% of cCMV infected children [3,4]. Both hearing loss and vestibular impairment can be present at birth, but can also develop in the first years of life. Furthermore, the course of symptoms can vary from being stable to fluctuating or progressive [4–8]. As the pathogenesis is not well understood and disease progression cannot be predicted, there is a heavy burden on patients and their parents.

Interestingly, there is another, more well-known inner ear disease that presents with similar fluctuating symptoms. Meniere's disease also causes vestibular symptoms such as vertigo and progressive and fluctuating hearing loss, in addition to tinnitus and aural fullness [9]. Endolymphatic hydrops is the major histopathological hallmark of this condition as has been demonstrated by post-mortem research. Nowadays it can also be visualized by a magnetic resonance imaging (MRI) sequence, named the 3D fluid attenuated inversion recovery (FLAIR), obtained 4 hours after intravenous contrast administration [10–13]. The

gadolinium-based contrast agent accumulates in the perilymphatic compartments of the inner ear, but not in the endolymphatic compartments. This enables radiologists to describe both compartments in relation to each other and to determine the presence of endolymphatic hydrops in both the cochlea and vestibular organs [14].

Since the clinical presentations of the two conditions resemble each other, endolymphatic hydrops may also play a role in cCMV cases presenting with fluctuating hearing loss or vestibular problems. This has previously been hypothesized based on results from post-mortem studies [15,16] and a case series [17]. Furthermore, a study in guinea pigs showed the development of endolymphatic hydrops and hearing loss upon injection of CMV into the endolymphatic sac of seronegative animals [18]. However, this hypothesis has never been tested in cCMV patients, as imaging techniques previously lacked sensitivity. This has changed with the current development of the 3D FLAIR MRI.

Here, we present a child with cCMV showing late-onset fluctuating inner ear symptoms. After a relapse, a 3D FLAIR MRI was made to investigate the presence of endolymphatic hydrops.

\* Corresponding author.

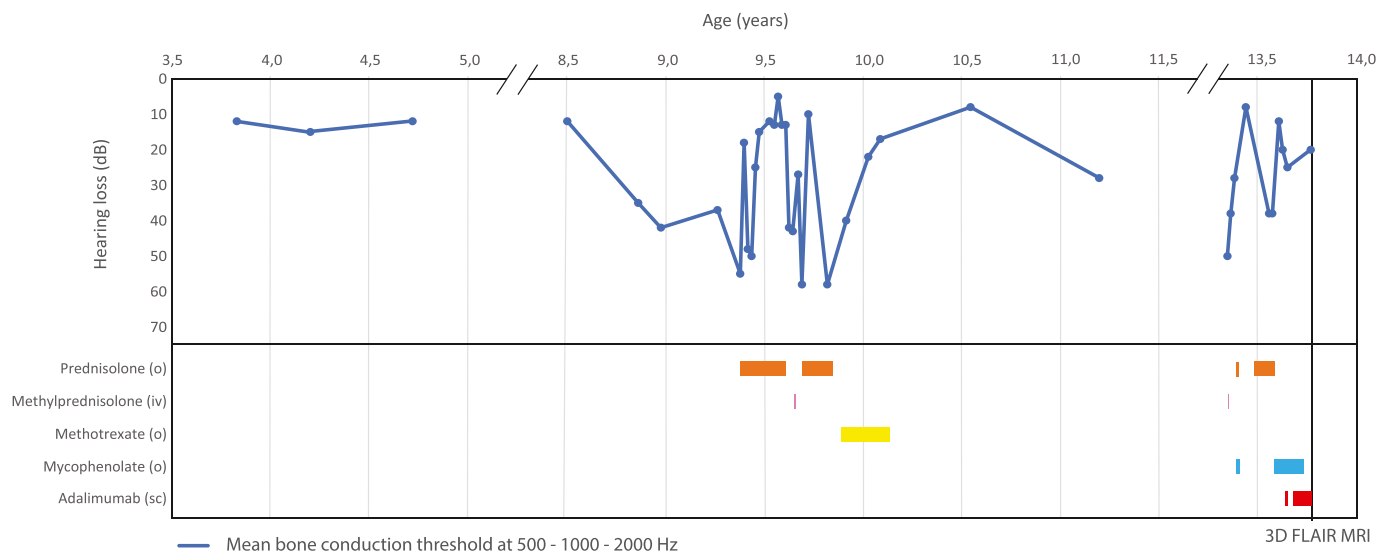
E-mail addresses: [l.c.m.grijpink@lumc.nl](mailto:l.c.m.grijpink@lumc.nl) (L.C.M. Grijpink), [a.c.t.m.vossen@lumc.nl](mailto:a.c.t.m.vossen@lumc.nl) (A.C.T.M. Vossen), [t.d.bruintjes@lumc.nl](mailto:t.d.bruintjes@lumc.nl) (T.D. Bruintjes), [b.m.verbist@lumc.nl](mailto:b.m.verbist@lumc.nl) (B.M. Verbist), [h.locher@lumc.nl](mailto:h.locher@lumc.nl) (H. Locher), [j.c.rotteveel@lumc.nl](mailto:j.c.rotteveel@lumc.nl) (L.J.C. Rotteveel).

<https://doi.org/10.1016/j.xocr.2023.100552>

Received 5 May 2023; Accepted 28 June 2023

Available online 29 June 2023

2468-5488/© 2023 Elsevier Inc. This is an open access article under the CC BY license (<http://creativecommons.org/licenses/by/4.0/>).



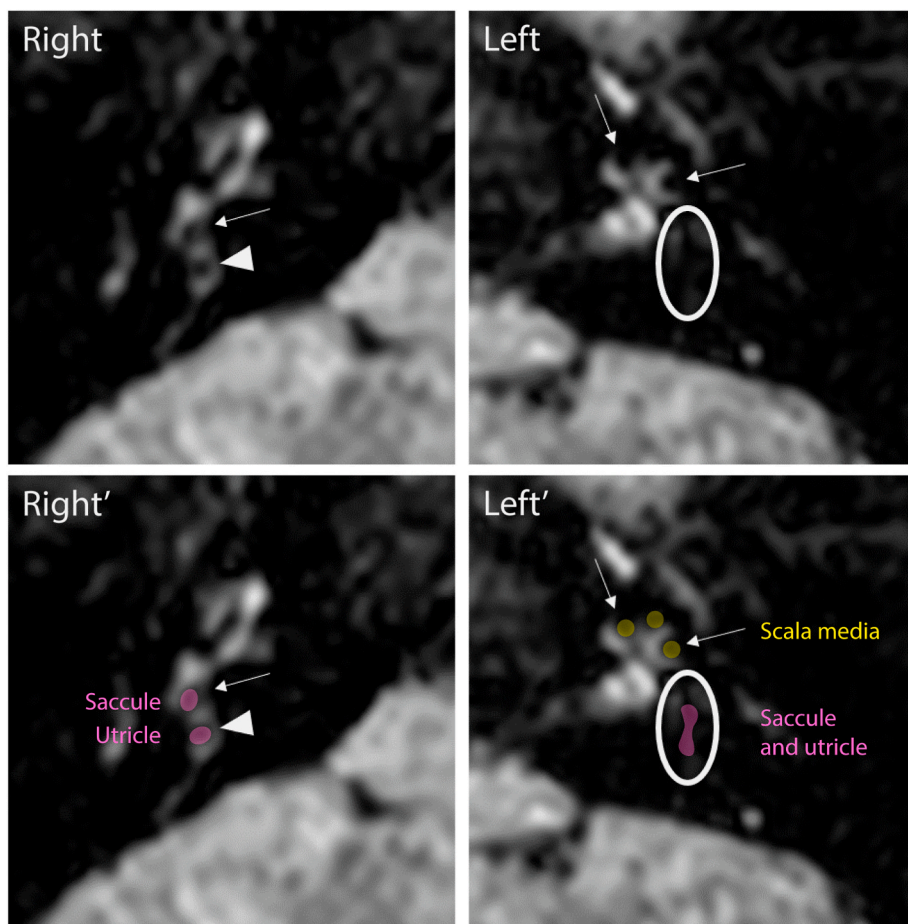
**Fig. 1.** Timeline displaying the course of hearing loss in the left ear in relation to the prescribed immune-modulating medication in a patient with congenital cytomegalovirus infection. The course of hearing loss is depicted as the bone conduction threshold through time. Medication was administered orally (o), intravenously (iv) or subcutaneously (sc). 3D fluid attenuated inversion recovery (FLAIR) magnetic resonance imaging (MRI) was performed at the age of 13.

1.1. Case report

The detailed course of hearing loss in the left ear of our patient in relation to the prescribed immune-modulating medication is shown in Fig. 1.

A 3-year old boy initially presented with delayed speech, language

development and asymmetric bilateral hearing loss. He had passed the newborn hearing screening. Otoscopy showed otitis media with effusion (OME) on the left side and no abnormalities on the right side. Audiometry showed mixed hearing loss in the left ear with a low frequency SNHL of 25 dB and an additional air-bone-gap (ABG) of 25 dB at all frequencies. Hearing threshold in the right ear was 82 dB Fletcher Index.



**Fig. 2.** 3D fluid-attenuated inversion recovery (FLAIR) magnetic resonance imaging (MRI) in a 13 year old patient with inner ear symptoms and congenital cytomegalovirus infection. Anatomical structures are illustrated in the two bottom images. Right: Normal appearance of the cochlea. Mild isolated vestibular endolymphatic hydrops, as the saccule (arrow) is equal in size to the utricle (arrowhead). In a healthy individual the size of the saccule is smaller than the utricle. Left: Moderate cochlear and severe vestibular hydrops, as shown by dilatation of the scala media (arrows) and effacement of the perilymphatic space in the vestibule (oval) due to enlargement and confluence of the saccule and utricle.

He also had microcephaly, hypermetropia and behavioral problems in addition to a delayed motor development for which he had received physiotherapy. Genetic testing ruled out mutations in GJB2 and GJB6 genes. Congenital CMV (cCMV) infection was diagnosed by CMV PCR on the neonatal dried blood spot. He received a hearing aid on the better hearing left side. During audiometric follow up according to the protocol for children with cCMV the low frequencies showed an improved bone conduction (BC) threshold of 10 dB with variable ABG in the left ear and stable, poor hearing outcome in the right ear at age 4.

After a few stable years he experienced worsening of hearing loss in the left ear at age 8. Audiometry showed SNHL of up to 50 dB at 500 Hz (currently with a spontaneously resolved ABG). MRI of the cerebellopontine angle showed no abnormalities, specifically no signs of inflammation of the vestibulocochlear nerve or congenital inner ear malformations. Although screening laboratory testing for autoimmune disorders was negative, after sudden further deterioration to a BC threshold of 55 dB, prednisolone was administered to treat for possible autoimmune inner ear disease (AIED). The treatment showed an initial effect after 6 days as the hearing loss recovered to a BC threshold of 18 dB. Upon dose reduction, the hearing loss increased again to a BC threshold of 48 dB. Due to side-effects, prednisolone was replaced by methylprednisolone pulse therapy and later methotrexate during which the hearing loss continued to fluctuate. Strikingly, upon termination of all treatments the low-frequency SNHL improved.

At age 13, he again indicated decreased hearing in his only-hearing left ear. The audiogram showed a SNHL of 50 dB at all frequencies. He also experienced recurrent episodes of tinnitus, vertigo and nausea. Despite several immunosuppressive treatments for suspected AIED, such as prednisolone, methylprednisolone pulse therapy, mycophenolate and adalimumab, his hearing remained unstable.

Vestibular tests were performed during adalimumab treatment. The video-head impulse test showed normal high-frequency test results in all six semicircular channels, rotational chair test showed bilateral low-frequency vestibular hypofunction, caloric testing bilateral low-frequency areflexia and cervical vestibular evoked myogenic potentials (VEMP) responses were bilaterally absent.

Another MRI scan was made, this time including the 3D FLAIR sequence. It showed a mildly dilated endolymphatic compartment of the sacculle on the right side. On the left side dilation of the scala media and effacement of the perilympatic space in the vestibule due to enlargement and confluence of the endolymphatic compartments of the sacculle and utricle were seen (Fig. 2). Since hearing fluctuations continued to occur during all immunosuppressive treatment, eventually all treatment regimens were terminated.

## 2. Discussion

This is the first reported case of a child with cCMV who was subjected to the 3D FLAIR MRI technique.

Similarities in the fluctuating pattern of inner ear symptoms in Meniere's disease and cCMV raise the question whether the two conditions also share a pathogenic mechanism resulting in or involving endolymphatic hydrops. Several post-mortem studies, a case series and an animal study suggested endolymphatic hydrops in fluctuating hearing loss in cCMV [15–18]. Until recently, however, it was not possible to test this hypothesis in humans *in vivo*.

The 3D FLAIR MRI technique has been developed to visualize endolymphatic hydrops for the diagnosis of Meniere's disease. Later, endolymphatic hydrops was also identified in AIED. In a cohort of 12 patients with primary immune-mediated inner-ear disease, 11 exhibited endolymphatic hydrops [19]. In contrast, only 1 of 5 patients with secondary immune-mediated inner ear disease showed endolymphatic hydrops. Interestingly, this specific case was a patient with both autoimmune thyroiditis and cCMV, and who showed the highest degree of endolymphatic hydrops on MRI of the cohort. The authors already speculated that cCMV itself could explain the endolymphatic hydrops in

this specific case.

Our case showed cochlear and vestibular hydrops shortly after worsening of inner ear symptoms, which again suggests that endolymphatic hydrops can be found in relation to fluctuating hearing loss in this patient group. However, the question remains how endolymphatic hydrops develops. In Meniere's disease, the leading hypothesis is a disturbance of ion homeostasis and the regulation of fluid volume in the inner ear [20,21]. Similarly, ion imbalance may be present in cCMV. Cytomegalic inclusion bodies have been found mostly in the stria vascularis and dark cell epithelium in post-mortem studies [15,22,23], which are involved in maintaining the ion balance. Furthermore, in a mouse model a decrease in expression of a  $K^+$  ion channel protein and a reduction of the endocochlear potential following a CMV infection have been shown [24,25]. In addition to direct viral damage, indirect damage caused by an immune response may play a role in hearing loss, which may explain the initial response to the prednisone treatment in this patient [26].

Ideally, sequential 3D FLAIR MRI scans could be performed at various times, including in the absence of symptoms, to strengthen the relationship between the presence of symptoms and endolymphatic hydrops. It should also be noted that mild endolymphatic hydrops is present in 31% of healthy adults, compared to 82.3% in Meniere's disease patients [27]. In our case, the right ear showed only saccular endolymphatic hydrops. The severe hearing loss on this side was known since the age of 3, hence cochlear involvement was also expected. Reasons for this discrepancy remain unknown. However, severe hearing loss in patients with isolated saccular hydrops has been described in a cohort study of patients with Meniere's disease [28]. Moreover, it is not known how long endolymphatic hydrops persists, thus it is possible that it was present at earlier age. Therefore, future studies should consider including multiple measuring time points in addition to a healthy control group. However, the impact of this scan for patients, especially children, should not be underestimated as it involves administration of contrast reagent and a 4 hour waiting time before the scanning process can start. As for now, the presence of hydrops does not alter treatment options.

## 3. Conclusion

The pathogenesis of late-onset fluctuating hearing loss and vestibular symptoms after cCMV infection remains elusive, hampering prognosis and treatment. This case shows that the 3D FLAIR MRI sequence can provide insight into the pathogenic mechanism of cCMV-induced hearing loss. Larger studies could bring us one step closer to uncovering this mechanism.

## Declaration of competing interest

Authors confirm that there are no known conflicts of interest associated with this publication.

## Acknowledgements

Informed consent was obtained for this case report. This work was supported by the Novo Nordisk Foundation (NNF21CC0073729 to Heiko Locher).

## References

- [1] Dollard SC, Grosse SD, Ross DS. New estimates of the prevalence of neurological and sensory sequelae and mortality associated with congenital cytomegalovirus infection. *Rev Med Virol* 2007;17:5 355–363. <https://www.ncbi.nlm.nih.gov/pubmed/17542052>.
- [2] Lanzieri TM, Dollard SC, Bialek SR, Grosse SD. Systematic review of the birth prevalence of congenital cytomegalovirus infection in developing countries. *Int J Infect Dis* 2014;22:44–8. <https://www.ncbi.nlm.nih.gov/pubmed/24631522>.

- [3] Grosse SD, Ross DS, Dollard SC. Congenital cytomegalovirus (CMV) infection as a cause of permanent bilateral hearing loss: a quantitative assessment. *J Clin Virol* 2008;41:2 57–62. <https://www.ncbi.nlm.nih.gov/pubmed/17959414>.
- [4] Dhondt C, Maes L, Rombaut L, et al. Vestibular function in children with a congenital cytomegalovirus infection: 3 Years of follow-up. *Ear Hear* 2021;42:1 76–86. <https://www.ncbi.nlm.nih.gov/pubmed/32590628>.
- [5] Fowler KB, McCollister FP, Dahle AJ, Boppana S, Britt WJ, Pass RF. Progressive and fluctuating sensorineural hearing loss in children with asymptomatic congenital cytomegalovirus infection. *J Pediatr* 1997;130:4 624–630. <https://www.ncbi.nlm.nih.gov/pubmed/9108862>.
- [6] Goderis J, Keymeulen A, Smets K, et al. Hearing in children with congenital cytomegalovirus infection: results of a longitudinal study. *J Pediatr* 2016;172: 110–115 e112. <https://www.ncbi.nlm.nih.gov/pubmed/26858192>.
- [7] Corazzi V, Hatzopoulos S, Bianchini C, et al. Vestibular and postural impairment in congenital Cytomegalovirus infection. *Int J Pediatr Otorhinolaryngol* 2022;152: 111005. <https://www.ncbi.nlm.nih.gov/pubmed/34894538>.
- [8] Chebib E, Maudoux A, Benoit C, et al. Audiovestibular consequences of congenital cytomegalovirus infection: greater vulnerability of the vestibular part of the inner ear. *Ear Hear*; 2022. <https://www.ncbi.nlm.nih.gov/pubmed/35687026>.
- [9] Lopez-Escamez JA, Carey J, Chung WH, et al. Diagnostic criteria for Meniere's disease. *J Vestib Res* 2015;25:1 1–7. <https://www.ncbi.nlm.nih.gov/pubmed/25882471>.
- [10] Hallpike CS, Cairns H. Observations on the pathology of meniere's syndrome: (section of otology). *Proc Roy Soc Med* 1938;31:11 1317–1336. <https://www.ncbi.nlm.nih.gov/pubmed/19991672>.
- [11] Fiorino F, Pizzini FB, Beltramello A, Mattellini B, Barbieri F. Reliability of magnetic resonance imaging performed after intratympanic administration of gadolinium in the identification of endolymphatic hydrops in patients with Meniere's disease. *Otol Neurotol* 2011;32:3 472–477. <https://www.ncbi.nlm.nih.gov/pubmed/21307806>.
- [12] Nakashima T, Naganawa S, Sugiura M, et al. Visualization of endolymphatic hydrops in patients with Meniere's disease. *Laryngoscope* 2007;117:3 415–420. <https://www.ncbi.nlm.nih.gov/pubmed/17279053>.
- [13] Gurkov R, Pyyko I, Zou J, Kentala E. What is Meniere's disease? A contemporary re-evaluation of endolymphatic hydrops. *J Neurol* 2016;263(Suppl 1):S71–81. <https://www.ncbi.nlm.nih.gov/pubmed/27083887>.
- [14] Connor SEJ, Pai I. Endolymphatic hydrops magnetic resonance imaging in Meniere's disease. *Clin Radiol* 2021;76. 1 76 e71-76 e19, <https://www.ncbi.nlm.nih.gov/pubmed/32892985>.
- [15] Myers EN, Stool S. Cytomegalic inclusion disease of the inner ear. *Laryngoscope* 1968;78:11 1904–1915. <https://www.ncbi.nlm.nih.gov/pubmed/4301925>.
- [16] Rarey KE, Davis LE. Temporal bone histopathology 14 years after cytomegalic inclusion disease: a case study. *Laryngoscope* 1993;103:8 904–909. <https://www.ncbi.nlm.nih.gov/pubmed/8395628>.
- [17] Huygen PL, Admiraal RJ. Audiovestibular sequelae of congenital cytomegalovirus infection in 3 children presumably representing 3 symptomatically different types of delayed endolymphatic hydrops. *Int J Pediatr Otorhinolaryngol* 1996;35:2 143–154. <https://www.ncbi.nlm.nih.gov/pubmed/8735410>.
- [18] Fukuda S, Keithley EM, Harris JP. The development of endolymphatic hydrops following CMV inoculation of the endolymphatic sac. *Laryngoscope* 1988;98:4 439–443. <https://www.ncbi.nlm.nih.gov/pubmed/2832669>.
- [19] Lobo D, Tunon M, Villarreal I, Brea B, Garcia-Berrocal JR. Intratympanic gadolinium magnetic resonance imaging supports the role of endolymphatic hydrops in the pathogenesis of immune-mediated inner-ear disease. *J Laryngol Otol* 2018;132:6 554–559. <https://www.ncbi.nlm.nih.gov/pubmed/29888688>.
- [20] Rizk HG, Mehta NK, Qureshi U, et al. Pathogenesis and etiology of Meniere disease: a scoping review of a century of evidence. *JAMA Otolaryngol Head Neck Surg* 2022;148:4 360–368. <https://www.ncbi.nlm.nih.gov/pubmed/35142800>.
- [21] Merchant SN, Adams JC, Nadol Jr JB. Pathophysiology of Meniere's syndrome: are symptoms caused by endolymphatic hydrops? *Otol Neurotol* 2005;26:1 74–81. <https://www.ncbi.nlm.nih.gov/pubmed/15699723>.
- [22] Teissier N, Delezoide AL, Mas AE, et al. Inner ear lesions in congenital cytomegalovirus infection of human fetuses. *Acta Neuropathol* 2011;122:6 763–774. <https://www.ncbi.nlm.nih.gov/pubmed/22033878>.
- [23] Gabrielli L, Bonasoni MP, Santini D, et al. Human fetal inner ear involvement in congenital cytomegalovirus infection. *Acta Neuropathol Commun* 2013;1:63. <https://www.ncbi.nlm.nih.gov/pubmed/24252374>.
- [24] Melnick M, Jaskoll T. An in vitro mouse model of congenital cytomegalovirus-induced pathogenesis of the inner ear cochlea. *Birth Defects Res A Clin Mol Teratol* 2013;97:2 69–78. <https://www.ncbi.nlm.nih.gov/pubmed/23281115>.
- [25] Yu Y, Shi K, Nielson C, et al. Hearing loss caused by CMV infection is correlated with reduced endocochlear potentials caused by stria damage in murine models. *Hear Res* 2022;417:108454. <https://www.ncbi.nlm.nih.gov/pubmed/35131579>.
- [26] Bradford RD, Yoo YG, Golemac M, Pugel EP, Jonjic S, Britt WJ. Murine CMV-induced hearing loss is associated with inner ear inflammation and loss of spiral ganglia neurons. *PLoS Pathog* 2015;11:e1004774. 4, <https://www.ncbi.nlm.nih.gov/pubmed/25875183>.
- [27] van der Lubbe M, Vaidyanathan A, Van Rompaey V, et al. The "hype" of hydrops in classifying vestibular disorders: a narrative review. *J Neurol* 2020;267. Suppl 1 197-211, <https://www.ncbi.nlm.nih.gov/pubmed/33201310>.
- [28] Maxwell AK, Ishiyama G, Karnezis S, Ishiyama A. Isolated saccular hydrops on high-resolution MRI is associated with full spectrum meniere's disease. *Otol Neurotol* 2021;42:6 876–882. <https://www.ncbi.nlm.nih.gov/pubmed/33481544>.